CHASM
Collaborating Hospitals Audit of Surgical Mortality

SCIDUA
Special Committee Investigating Deaths Under Anaesthesia

Message from the Chairmen

Dear Colleagues and Health Professionals,

The inaugural joint forum meeting between the Collaborating Hospitals' Audit of Surgical Mortality (CHASM) Committee and the Special Committee Investigating Deaths Under Anaesthesia (SCIDUA) discussed a case that was reviewed by both programs.

Following the joint forum case review an outcomes paper was prepared for the purpose of sharing the clinical learnings to support safety improvement practices throughout New South Wales.

The Minister for Health, The Hon. Brad Hazzard M.P. has approved the disclosure of the specially privileged information collected by both programs. This information is presented in a deidentified manner to protect anonymity and remove potential bias.

It is our hope that the recommendations of the joint forum and the information in the case example will offer an insight into complex surgical procedures and encourage peer-based discussions that may develop further systemic improvements.

We would also like to take this opportunity to extend our gratitude to the medical practitioners involved in CHASM and SCIDUA for their contributions, and to the members of the Committees for their ongoing dedication and commitment.

Yours sincerely,

Dr David Robinson
CHASM Chairman

Dr Carl D'Souza
SCIDUA Chairman

Collaborating Hospitals' Audit of Surgical Mortality
CEC-CHASM@health.nsw.gov.au

Special Committee Investigating Deaths Under Anaesthesia
CEC-SCIDUA@health.nsw.gov.au

NSW GOVERNMENT

CLINICAL EXCELLENCE COMMISSION

DECEMBER 2019

Joint Forum

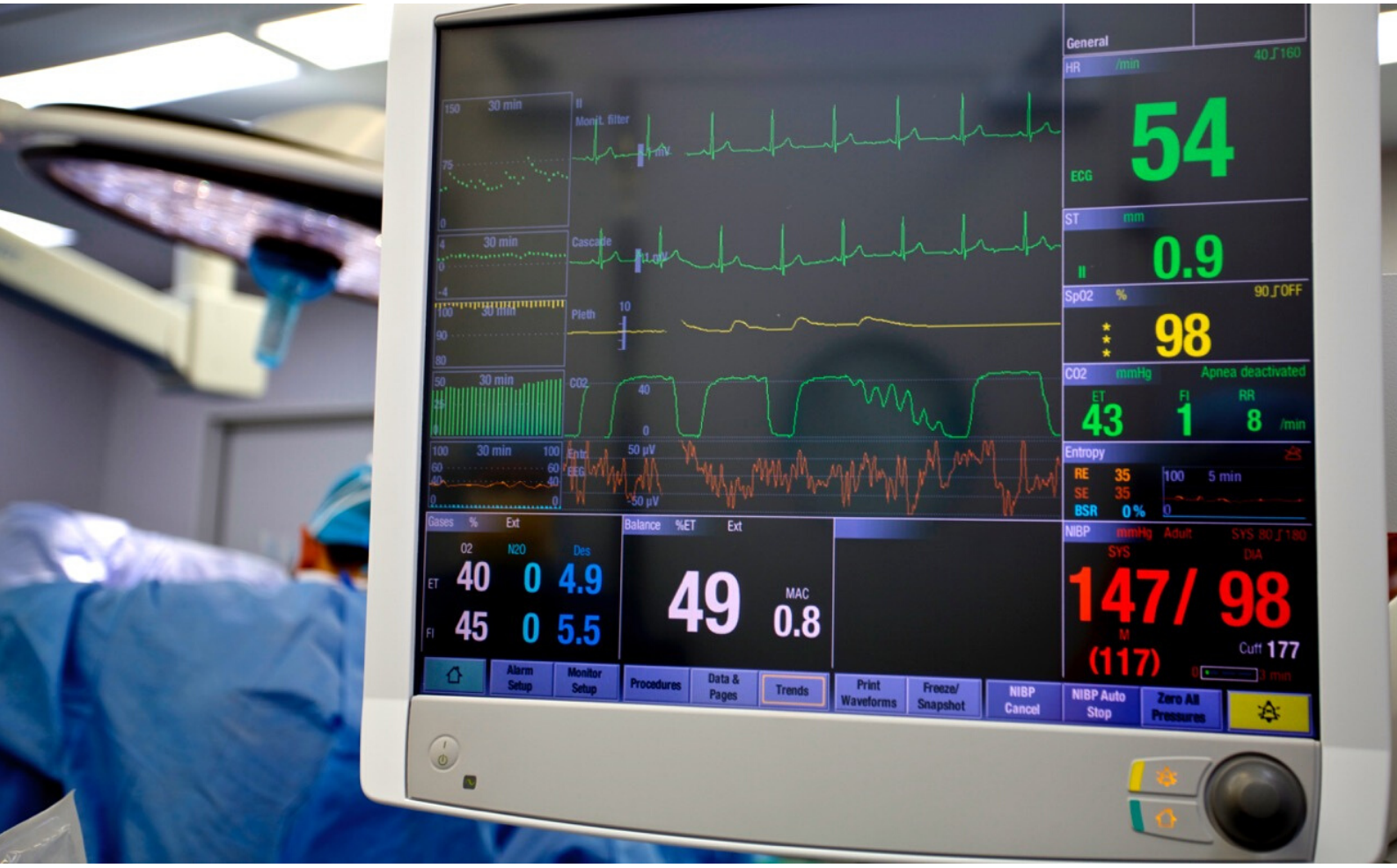

OUTCOME PAPER NO. 1

The first joint case review by CHASM and SCIDUA

DISCLAIMER

All identifying information has been omitted to preserve anonymity.

National Library of Australia Cataloguing-in Publication entry

Title: Outcome Paper No. 01, 2019 – CHASM and SCIDUA Joint Forum

SHPN: (CEC) 200339
ISBN: 978-1-76081-437-3

Contributors: Dr David Robinson, Dr Carl D'Souza, Dr Robert Costa, Dr David Blomberg, Dr Drew Dixon, Dr Elizabeth O'Hare, Dr Michele O'Brien, Professor Mark Wiggins, Carrie Marr, Dr James Mackie and Lisa Ochiel.

Editors: Dr David Robinson, Dr Carl D'Souza, Dr Robert Costa, Dr David Blomberg, Lisa Ochiel, John Carrick and Katherine Asher.

Cover Photo: Dr Ji Young Heo, VMO Anaesthetist.

Suggested citation

Clinical Excellence Commission, 2019. *Outcome Paper No. 01, 2019 – CHASM and SCIDUA Joint Forum.* Sydney, Australia.

CLINICAL EXCELLENCE COMMISSION

Any enquiries about or comments on this publication should be directed to:

Manager, Special Committees Program
Clinical Excellence Commission
Locked Bag 8
HAYMARKET NSW 1240

Phone: (02) 9269 5531

Email: lisa.ochiel@health.nsw.gov.au

NSW GOVERNMENT

CLINICAL EXCELLENCE COMMISSION

SCIDUA
Special Committee Investigating Deaths Under Anaesthesia

CHASM
Collaborating Hospitals Audit of Surgical Mortality

Joint Forum Meeting

Background
As an initiative of the Clinical Excellence Commission an inaugural meeting of members from both Ministerial Committees (CHASM and SCIDUA) was held to discuss a single case which met the criteria for both Committees' Terms of Reference.

Case Setting
General Surgery case at an acute group A hospital for elective surgery on a private patient requiring repair of a type III para-oesophageal hernia.

Patient was 75 years of age, with co-existing factors listed as: cardiovascular, respiratory, obesity and age.

- The operating surgeon assessed the patient as an ASA3
- Overall risk of death before the surgery was assessed as small by the surgeon
- Patient admitted on a Thursday

Appropriate DVT prophylaxis was used for this surgery including Heparin, TED stockings and sequential compression device.

Objectives

1. To assess the various mortality review outcomes presented for this case to identify any areas of improvement in the review processes of both programs
2. To assess whether a joint retrospective review of the case, with the additional information provided from RCA and autopsy, provides further perspective to the determinations made
3. To form recommendations and present the findings to medical practitioners for clinical education and patient safety purposes.

Recommendations

From the combined information gathered for this case, the additional reports provided, and with the benefit of hindsight, the participants were able to discuss the various clinical aspects of the case, the events leading up to the patient's death, potential areas of concern, and any deficiencies in the review processes.

Initially the group spoke about the need for clinical engagement and promoting these learnings at different hospital forums such as Grand Rounds and M&M meetings. The group discussed the importance of open, supportive communication amongst teams, and the need to ensure that students and other junior surgeons are well-supported in their learning environment. They should be encouraged to ask questions amongst their peers and to senior surgeons. Surgical leadership should reinforce the positive and demonstrate good practice.

Recommendation 1: Hospitals should focus on developing an "Asking Without Shame" environment as an important step towards building a positive safety culture, where patient outcomes are the main driving force.

Message: Asking for a senior practitioner to assist, is the mark of a good medical practitioner.

Discussions on the clinical aspects of the case included debate on whether an earlier CT scan or the use of echocardiogram in the absence of a practitioner with experience conducting a pericardiocentesis would have made a difference to the patient's outcome. Weekend rostering, and the difficulties and delays that can be experienced, was also an issue raised.

Expert opinion provided: It may only require 150mls or less of blood in an un-dilated pericardium to cause a cardiac tamponade, although there should be symptoms, such as compromised breathing, indicating the patient is in difficulty. Overall, this was a difficult case where all the right things were done from a surgical point of view, but an unfortunate patient outcome was not able to be avoided.

The group agreed that in cases such as this, tachycardia and oliguria should be investigated early, particularly in settings where there may not be other signs of sepsis (for example, an abnormality in the blood count, or acidosis).

Conclusion: This was a situation where the least common diagnosis was not the one first thought of when considering possibilities for treating this patient. This case was a combination of unusual circumstances with a rare complication for this type of surgery.

Recommendation 2: This case should be used as a stand-alone example to support the decision-making in the various presentations of challenging cases such as this one.

The experience of the surgeon is important in determining the patient outcome, and consideration should be given to a variety of operative approaches and techniques for this disease, even if no cardiovascular comorbidities or risk factors are known at presentation.

Message: A pericardiocentesis is not a simple procedure to perform, and not a task for the inexperienced.

Note: Following this case a thorough review was conducted at the hospital. This particular surgery was suspended for several months, before recommencing under a new protocol.

Addressing the forum objective to assess the review processes of both programs, the group concluded that the strength of the mortality reviews conducted by CHASM and SCIDUA lies with the candid account of the medical practitioner.

For CHASM, an independent peer assessment is conducted on the clinical information provided by the operating surgeon for their case, including whether there were any aspects of concern to contemplate. The review provides the assessor with an opportunity to reflect, as well as providing feedback to the surgeon from a professional of the same specialty.

For SCIDUA, the Committee assesses the case information provided and determines the classification for the causality of the mortality. Following the Committee meeting, feedback from the Chair is provided to the anaesthetist / sedationist along with any relevant advice.

The key point of efficacy for these programs is in the timeliness of the notifications of death provided by Hospitals and in the responses provided by the participating medical practitioners.

Recommendation 3: The Committee Chairs encourage the self-reporting of mortality cases.

Message: The quality of the information provided in response to the specific questions asked for each program creates a unique dataset not collected anywhere else.

Additional information provided for the Joint Forum
A copy of the report from the Root Cause Analysis (RCA) was provided to the group. The report recommended discussion at Clinical Council, possibly leading to the development of a clinical guideline. CHASM was advised by the Hospital's Department Head that a new protocol was implemented – *to conduct an echocardiogram before discharging the patient from ICU* - with positive results demonstrated in the surgeries completed.

A copy of the autopsy report from the Coroner was also provided to the group. The Coroner's Report noted one of the discussion points as: *If there are ongoing issues of care and treatment, it may be helpful for this case to be reviewed by a cardiothoracic surgeon.* In response, CHASM conducted a further review of the case from a cardiothoracic perspective.

CASE EXAMPLE - CHASM

Cardiothoracic and General Surgery (Upper Gastrointestinal)

Part 1: Case details provided to the Collaborating Hospitals' Audit of Surgical Mortality

Case Setting
General Surgery case at an acute group A hospital for elective surgery on a private patient requiring repair of a type III para-oesophageal hernia.

Patient was 75 years of age, with co-existing factors listed as: cardiovascular, respiratory, obesity and age.

- The operating surgeon assessed the patient as an ASA3
- Overall risk of death before the surgery was assessed as small by the surgeon
- Patient admitted on a Thursday

Appropriate DVT prophylaxis was used for this surgery including Heparin, TED stockings and sequential compression device.

Operating surgeon's comments on the course to death
A four-hour operation was undertaken by the surgical consultant with a consultant anaesthetist present and a surgical fellow and SET Trainee assisting - Laparoscopic adhesiolysis and mesh repair (glue fixation) of a large incarcerated recurrent type III paraoesophageal hernia.

On the morning of the 2nd post-operative day (Saturday) the patient was cleared by the HDU team to be transferred to the surgical ward. Few hours later, the patient started complaining of breathing difficulties with drop of urine output. The patient became rapidly unstable with breathlessness, requiring intubation.

An emergency chest CT-scan established the diagnosis of cardiac tamponade, unfortunately a pericardial drain could not be inserted due to the lack of an interventional radiologist. The cardiologist and intensivist on site were also contacted, but unfortunately neither of them had the skills to perform a pericardiocentesis. The Consultant surgeon was notified but was 50 minutes away from the Hospital at a Conference, and the surgical registrar on duty was left alone to perform their first emergency pericardiocentesis in ICU.

Unfortunately, by the time the Consultant surgeon arrived on site, the patient had suffered a cardiac arrest necessitating CPR which was unsuccessful. An open pericardiocentesis was performed in ICU. The patient was then transferred to the operating theatre for completion of their emergency surgery (including insertion of bilateral chest drains).

Sadly, the patient rapidly became coagulopathic and was bleeding from multiple surgical sites including drain sites. and developed MOF (Multi-Organ Failure), passing away few hours later.

Areas of consideration or concern
The surgeon specified that there was a delay in the diagnosis of cardiac tamponade from the HDU team, and stated that post-operative care could have been improved. Issues outlined:

1. Delay in clinical diagnosis of cardiac tamponade in HDU which *may have contributed* to the patient's death and was *probably* preventable.
2. No access to interventional radiology on site which *may have contributed* to the patient's death and was *probably* preventable.
3. Sub-optimal clinical cover to perform emergency pericardiocentesis on weekends which *may have contributed* to the patient's death.

Reflections of the surgeon
This 75 year old patient initially underwent emergency laparoscopic repair of incarcerated (volvulus) paraoesophageal hernia 6 years ago. The decision to operate for the second time was not made lightly and only after multiple discussions with the patient, spouse, and the patient's multiple treating doctors (gastroenterologist, cardiologist, GP).

The significantly higher risks of a second similar operation were also discussed, but due to the severity of the patient's symptoms that were affecting daily quality of life, the patient was willing to go ahead with the surgery.

The surgery was difficult, mainly due to the degree of fibrosis in the mediastinum, but went extremely well with minimum blood loss. As per standard practice, the Consultant surgeon glued the mesh on the crus with Tisseel (fibrin glue used for the last 9 years) as staples are well known to potentially lead to cardiac tamponade.

The patient was transferred to HDU for monitoring, and a chest X-ray on day one post-operative was normal. The patient was tolerating fluids and had minimum discomfort. There was minimal output from the drain and the patient was cleared to be transferred to the ward.

It seems that the diagnostic delay was mainly due to the fact that the patient was compensating very well, despite the progressing cardiac tamponade. The patient was maintaining a normal BP, but remained tachycardic (which was common for this patient). The drop in urine output was probably overlooked.

Incident Management
Since this catastrophic event, the Consultant surgeon requested an RCA in order to address the three important issues that were most likely detrimental to the patient:

1. Delayed diagnosis of cardiac tamponade
2. Absence of interventional radiology in a busy principal referral group A 1B hospital with tertiary affiliations to universities
3. Limited access to emergency pericardiocentesis on weekends

Following the submission of the operating surgeon's surgical case form to the CHASM program it was reviewed for completeness, coded and assigned to an independent peer of the same specialty to undergo First Line Assessment.

Part 2: Independent Peer Review - First Line Assessment

Initial Case Assessment
Medical admission notes, medical follow-up notes, procedure notes and case summary letter to GP were all assessed as satisfactory.
Assessor's view before surgery of overall risk of death was considered as small.

Assessor's stated Area of Consideration, Concern or Adverse Event
Delayed treatment of large pericardial effusion due to lack of qualified personnel, which caused death of patient who would otherwise be expected to survive. It was determined that this was *probably preventable* and was associated with another clinical team and the hospital.

Following the submission of the First Line Assessment to the CHASM program it was reviewed for completeness and coded. As the recommendation was to proceed to Second Line Assessment – this is where a full case note review is undertaken by another independent peer group assessor – the case was also discussed with the Chairman, CHASM Committee.

A request was then made to the hospital to provide a copy of the patient's medical record.

Part 3: Independent Case Note Review – Second Line Assessment

Case Review by the Assessor
This 75 year old patient had elective surgery for repair of a recurrent large para-oesophageal hiatus hernia on the 21 June 2018. History of hypertension, previous hip replacement surgery, non-insulin dependent diabetes mellitus, and sleep apnoea on CPAP. Also previous surgery to repair a hiatus hernia and fundoplication in 2012.

Medications included: Sulfasalazine, Lercanidipine, Irbesartan, Hydrochlorothiazide, Atorvastatin, Metformin, and Aspirin (stepped one week prior to surgery).

The patient had a large recurrence of para-oesophageal hiatus hernia with pleural adhesions particularly right pleural adherent to oesophagus. The dissection was difficult due to amount of adhesions. The hiatal defect was closed with 0-Ethibond sutures and reinforced with a Bio A mesh glued to the crura and diaphragm. An anterior fundoplication was performed. A drain was placed in the left upper abdomen.

Patient recovery was as expected on Day 1 and 2. On the morning of Day 3 post-op, the patient had a heart rate of 123, Blood Pressure 102/71, Respiratory Rate 29, Oxygen saturation 98% on 1L NP. WCC 17, HB 122, CRP 118. Chest X-Ray showed bi-basal opacities. Patient continued to deteriorate.

A CT chest and abdomen was performed which showed a large pericardial effusion.

Pericardiocentesis was performed under ultrasound with 40ml of blood aspirated. Patient went into cardiac arrest. Pericardial window performed in ICU with improvement in haemodynamic. Patient returned to theatre.

There was insufficient information in the notes as to the site of bleeding. Floseal was applied to the mediastinum and a 19 Blake drain placed in the pericardial sac. Patient had 24 Units RBC, 15 Units Cryo, 19 Units FFP, and 3 pooled platelets.

Patient returned to ICU unstable and had further cardiac arrest. A decision was made not to continue treatment. The patient passed away shortly after.

Assessor's Conclusion
On review of the case notes, there were no issues identified with the preoperative decision making and technique. Despite being a difficult re-operative case, the operation was performed satisfactorily. Patient had an uneventful first two days in HDU and was discharged to the ward. Haemodynamically there were no signs to suggest pericardial effusion.

Perhaps a raised CRP would be a sign for early imaging. Having identified a pericardial effusion with haemodynamic instability, there were no qualified personnel to perform an urgent pericardiocentesis, which might have made a difference to the outcome of the patient.

Recommendation
This is an area of major concern which the teams and the hospital should address to prevent reoccurrence.

CASE EXAMPLE - SCIDUA

Case details provided using the SCIDUA Notification Form
The patient was assessed as an ASA 5.

Pre-operative diagnosis / condition
21 June 2018 – Patient admitted for elective paraoesophageal hernia repair complicated by pneumothorax and transferred to ICU.
23 June 2018 – At 16:00 hours haemodynamically unstable → CT chest performed → cardiac tamponade → failed pericardiocentsis in ICU → cardiac unit transferred to Operating Theatre, intubated and ventilated.

Operation / Procedure
Pericardial Window – Emergency

Findings
Drainage of pericardial blood.

Brief description of events
Patient transferred from ICU to OT by Anaesthetic Registrar. Anaesthetist attended soon after (on-call), patient was too unstable to be moved onto OT bed.
Upper middle laparotomy performed by general surgeon, with registrar.
Massive transfusion in progress – total 30 Units of blood products. Total blood loss was 2.35L.
Patient had severe acidosis.
Limited response to vasopressors (Noradenaline 64mls/hr of single strength 4mg/50mls.
Drained of blood from pericardium performed with pericardial drain.
Parameters at end of case: ABP 110/80. O_2 sats 92% (100% FiO_2). CO_2 25mg

Likely cause of death
Haemorrhage.

At the time of the patient's second surgical procedure the patient was assessed by the triage Committee as having a score of ASA 5. Additional anaesthesia-related information was requested from the hospital for the Chair to review prior to the joint forum.

Additionally, following discussion with the medical practitioner it seems the intensivist on this case was concerned that the patient may have suffered a bowel perforation.

The SCIDUA Triage Committee classified case as 4(01) - Surgical death where the administration of the anaesthesia is not contributory and surgical or other factors are implicated. - Patient died as a result of surgical bleeding.

SCIDUA
Special Committee Investigating Deaths Under Anaesthesia

CHASM
Collaborating Hospitals Audit of Surgical Mortality

Reference Points for Further Reading

- Performing surgery for a large para-oesophageal hernia is not a "one-size-fits-all" paradigm.[1]
- Literature reviewed on cases of laparoscopic hiatal hernia repair reported cases where cardiac tamponade developed from the intra-operative period up to day 14 post-op.[2]
- Cardiac tamponade is most often is the result of injury to the cardiac tissues or pericardium when applying staples or sutures during the placement of mesh.[3, 4]
- Yerdel et al (2018) reported that most graft-fixated related cardiac tamponades reviewed for their study resulted from a helical tack.[5]

Forum Participants
Dr David Robinson, CHASM, Chair
Dr Robert Costa, CHASM member
Dr David Blomberg, CHASM member
Dr Drew Dixon, CHASM member
Professor Mark Wiggins, CHASM member
Dr Carl D'Souza, SCIDUA, Chair
Dr Elizabeth O'Hare, SCIDUA member
Dr Michele O'Brien, SCIDUA member
Carrie Marr, Chief Executive, Clinical Excellence Commission (CEC)
Dr James Mackie, Medical Director, Medical Patient Safety, CEC
Lisa Ochiel, Senior Manager, Special Committees Program, CEC

Acknowledgement
The Clinical Excellence Commission would like to express its gratitude to the Committee members participating in this first-of-its-kind forum, and to the Special Committee Investigating Deaths Under Anaesthesia and the Collaborating Hospitals' Audit of Surgical Mortality Committee.

The feedback provided to the medical practitioners of New South Wales participating in these valuable peer review and reflection programs is appreciated.

Editors
Dr David Robinson
Dr Carl D'Souza
Dr Robert Costa Dr
David Blomberg
Lisa Ochiel
John Carrick
Katherine Asher

[1] Galey K.M., Watson T.J. (2011) Giant Paraesophageal Hernia: Optimal Surgical Approach. In: Ferguson M. (eds) Difficult Decisions in Thoracic Surgery. Springer, London. https://doi.org/10.1007/978-1-84996-492-0_36
[2] Y.E. Paz, J. Vazquez, M. Bessler, Cardiac tamponade as a complication of laparoscopic hiatal hernia repair: Case report and literature review, Catheter. Cardiovasc. Interv. 78 (2011) 819e821. https://doi.org/10.1002/ccd.23178
[3] C.T. Frantzides, S.N. Welle, Cardiac tamponade as a life-threatening complication in hernia repair, Surgery 152 (2012) 133e135. https://doi.org/10.1016/j.surg.2011.08.009
[4] W. Makarewicz, L. Jaworski, M. Bobowicz, K. Roszak, K. Jaroszewicz, J. Rogowski, et al., Paraesophageal hernia repair followed by cardiac tamponade caused by ProTacks, Ann. Thorac. Surg. 94 (2012) 87e89. https://doi.org/10.1016/j.athoracsur.2012.03.107
[5] Mehmet Ali Yerdel, Ozan Şen, Utku Zor, Simay Kara, and Bülent Acunaş.Journal of Laparoendoscopic & Advanced Surgical Techniques.Sep 2018.1041-1046. http://doi.org/10.1089/lap.2017.0713